

## POST COVID-19 MUCORMYCOSIS AND MAXILLARY SINUS – OUR EXPERIENCE

C. Karuppasamy<sup>1</sup>, K. Ramesh Babu<sup>2</sup>, S. Amrutha<sup>3</sup>, B. Ganesh Kumar<sup>1</sup>

Received : 20/11/2022  
Received in revised form : 31/12/2022  
Accepted : 15/01/2023

**Keywords:**

Mucormycosis, Maxillary Sinus, Amphotericin, Endoscopic Sinus Surgery, Pterygo Palatine Fossae, Infra Temporal Fossae, Maxillectomy.

**Corresponding Author:**

**Dr. B. Ganesh Kumar,**  
Email: drganeshkumarb@gmail.com

DOI: 10.47009/jamp.2023.5.4.35

Source of Support: Nil,  
Conflict of Interest: None declared

*Int J Acad Med Pharm*  
2023; 5 (4); 165-169



<sup>1</sup>Associate Professor, Department of ENT, Thanjavur Medical College, Thanjavur, India.

<sup>2</sup>Associate Professor, Department of ENT, Govt. Thiruvavur Medical College, Thiruvavur, India

<sup>3</sup>Assistant Professor, Department of ENT, Thanjavur Medical College, Thanjavur, India

### Abstract

**Background:** Mucor mycosis is a highly fatal disease in this Covid pandemic especially in Second wave. Commonly involved in reduced Immunity status like Uncontrolled Diabetes, on long term Steroid usage. Among the Para Nasal Sinuses Maxillary sinus is commonly involved. To study about the Maxillary sinus and its various wall involvement, to know about the extension especially to the adjacent regions like Orbit and Intra cranium, to know about the types of surgical treatments. Study Design is Retrospective Study, Analytical Study. **Materials and Methods:** Study was conducted in Dept of ENT, Govt Thanjavur Medical college. Period of study May -August 2021. Total number of cases are 132. All cases evaluated by clinical symptoms followed by DNE and Radiological evaluation. All cases underwent Endoscopic assisted debridement. Systemic Amphotericin given for all cases. Regular weekly follow up and Endoscopic cleaning of nasal cavity by Hypertonic saline done. **Result:** Males (86) are commonly affected. 21-40 years are more involved (88cases). Medial wall of maxillary sinus involved in more number (48) of cases, next one is Palatal involvement. Endoscopic Sinus Surgery commonly performed for 36cases, followed by Endoscopic Medial Maxillectomy (12 cases), and Pterigo Maxillary Fossae exposure and Infra Temporal Fossae Exposure in 23 cases. Strong Positive Association present between Diabetes and Post Covid Status seen in our study. Maxillary sinus involvement in Mucormycosis is most common than other sinuses. Early diagnosis with clinical findings such as Nasal Obstruction, Purulent Nasal Discharge, Numbness over Infra Orbital region, Ptosis, Loosening of tooth, Trismus due to Medial Pterygoid Muscle Involvement is crucial role in initiating the proper treatment. CT PNS and MRI plays Vital role to identify the extent of Devitalised Tissue by that the Type of Surgical Procedure can be decided. Operated Tissue Material sent for both Histopathological Examination and Fungal Culture, by that Post Operative Amphotericin started. Adequate Glycaemic Control is very important by that Disease Extension, complication and Mortality can be reduced. Regular Post Operative Follow up with Endo Cleaning is very effective in reducing Recurrence. **Conclusion:** Maxillary Sinus is commonly involved. Early clinical diagnosis with Supportive Radiological evidence is important for Early Surgical Debridement. Adequate Antifungal therapy is mandatory. Post operative Endo Cleaning with Step down therapy with Oral Antifungal agents is very important. Control of Predisposing factors plays vital role.

## INTRODUCTION

In 1885 Paulauf described the Zygomycosis or Phycomycosis which also known as Mucor. Most of the time this infection is opportunistic. Rapid spread and severe mortality are characteristic. Vascular invasion along the Inner layer of Elastic lamina is pathognomonic one.<sup>[1]</sup> Rhizopus, Abisidia, and Rhizomucor are other groups in this category. Mucor was stable against high temperature.

Natural Environment like Soil, animal faeces and Decaying Plant Materials are the sources of Mucor. It will infect the Immunocompromised and Uncontrolled Diabetes patients. It was the Most Common Invasive Fungal Lesion after Aspergillosis and Candidiasis.<sup>[2]</sup>

Portal of entry is always Nose and Paranasal sinuses mainly Maxillary sinus. Non Septate, Right Angled Branching Broad Hyphae entering into blood vessels and reach vital organs like Lungs, Brain and Orbit and causes Thrombosis followed by Tissue Necrosis.

Chronic Diabetes patients are vulnerable for local Tissue Ischemia and Infections, because of Microangiopathy and Atherosclerosis. So in Uncontrolled Diabetes with Mucormycosis of Maxillary sinus involved patients are more Vulnerable for Thrombosis of Internal Maxillary and Descending Palatine Artery results in Necrosis of Maxilla and Palate.<sup>[3]</sup>

Maxilla forms the Upper Jaw. It takes part in the formation of Palate, Nose and Orbit. Alveolar Process of Maxilla having the teeth and is very important for Mastication and Speech. Necrosis of Maxillae is very rare because of its high blood supply.<sup>[4]</sup>

Maxillary bone necrosis occurs in Bacterial infections like Osteomyelitis, Viral infections like Herpes Zoster, Fungal infections like MucorMycosis, Trauma and after Radiotherapy for the treatment of Sinonasal Malignancy.<sup>[5]</sup>

Overcrowding is main cause of high incidence in Developing countries like India. Environmental factors like Humid Climate and High temperature which favours for increased surveillance of Mucormycosis. Reviewing the Literature of past 5 decades (1960-2012) showed the Prevalence Rate for Mucormycosis was 0.14 cases per 1000 population.<sup>[6]</sup> Symptoms of Mucormycosis are Nasal Stuffiness, Infra Orbital Numbness, Palatal perforation. Infected Tissues appears normal at the earliest stage, then congested mucosa and finally leads Gangrenous Black Eschar. Direct spread to the adjacent regions like Hard Palate, Sphenopalatine and Greater palatine artery are common. Pain and Swelling of Palatal followed by separation of Mucosa from palate and Ultimately results in Palatal Perforation.<sup>[7]</sup>

Mucormycosis spread into the Pterygo Palatine Fossae and from there to Infra Temporal Fossae, through the erosion of Posterior wall of Maxilla. Symptoms are Difficulty in mouth opening and Unilateral facial swelling in Infra Temporal region. Through the Erosion of Orbital Floor, Intra and Extra Ocular muscles are involved resulting in Unilateral Peri Orbital pain, Ophthalmoplegia, Restricted Eye Movements, Head ache and Acute Vision loss.<sup>[8]</sup>

Pre-Maxillary region Swelling is common after the Erosion of Antero Lateral wall of Maxillary Sinus. All cases are Evaluated with CT and MRI Paranasal Sinuses and after getting various opinions like Ophthal, Dental Surgery, Neuro Surgery, and Diabetology. Patient was subjected to Various types of Surgical Debridement like Endoscopic Sinus Surgery, Denker's Procedure, and Maxillectomy depending upon the extension of disease. Systemic Amphotericin Injection Followed by Salvage therapy with Tablet Posaconazole is very important to reduce recurrence. Weekly Postoperative Endo cleaning is mandatory.

#### **Objectives:**

#### **Study about**

1. The Maxillary sinus and its various walls Involvement.

2. To Know the extension into adjacent regions.
  3. To know about the various types of Surgical Treatments used in Mucormycosis Management.
- Study Design:** Retrospective Study, Analytical Study.

## **MATERIALS AND METHODS**

Study was conducted in Thanjavur Medical College, Tamil Nadu, India, in Department of ENT and Head and Neck Surgery from May 2021 - August 2021. Total Number of patients are 132. Patients with limited Maxillary Sinus disease alone taken for study. Other Sinus involvement cases are Excluded. All cases are Evaluated by the Clinical Features like Nasal Obstruction, Swelling in Pre Maxillary region, Infra Orbital Numbness, Trismus, Infra Temporal Fossae Swelling. Diagnostic Nasal Endoscopy was done for all cases, which reveals the Block coloured Gangrenous ESCHAR diagnostic of Mucor mycosis. Radiological Investigation consists of CT PNS gives details about the Bony Boundaries. MRI is very important to know about the Viable status of soft tissues adjacent to Maxillary sinus especially in Pterygo Palatine Fossae. All patients underwent Early and Forcible Endoscopic Sinus Surgery and other approaches depending upon the Extension. Tissue Specimen sent for HPE and Fungal Culture and Started with Inj. Amphotericin. All are discharged and followed regularly with Endo Cleaning once in a week. All are Counselling regarding Importance of Management of their Individual Predisposing factors for the development of Mucor mycosis.

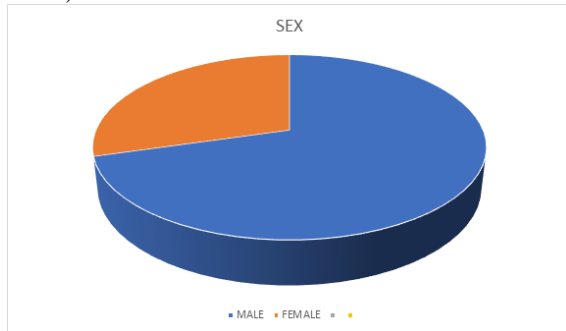
## **RESULTS**

In our Study Males (86cases) are predominantly affected than Females (36 cases). It was revealed in [Table 1 and Figure 1].

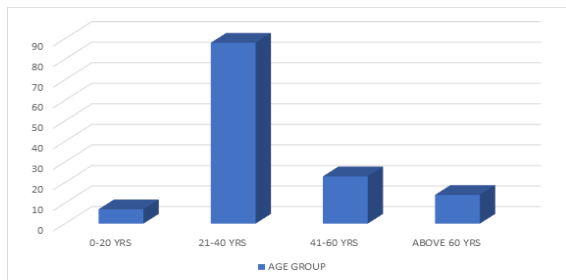
[Table 2 Figure 2] Shows the pattern of Age group representation. 88 patients belong to 21-40 years, followed by of 41-60 years of age group (23 cases) and 14 are Above 60 years of age group. Less than 20 years (07 cases) are affected very minimally.

[Table 3 and Figure 3] displays the various risk factors related to the development of Mucormycosis. Strong Positive Correlation present between Diabetes Mellitus, Steroid usage, Post Covid Status and the development of Mucormycosis in our study. Negative association with Oxygen treatment is seen. [Table 4 and Figure 4] explains the number of cases related to the site of involvement of Maxillary Sinus. Medial wall of Maxillary Sinus involved in 48 cases. Next major group 32 cases belong to Floor of Maxillary Sinus (Palate and Alveolar ridge involvement), followed by Posterior wall and extension into Pterygo Palatine Fossae and Infra Temporal Fossae is 23 cases, Antero lateral wall and Pre Maxillary region in 19 cases. 10 patients are

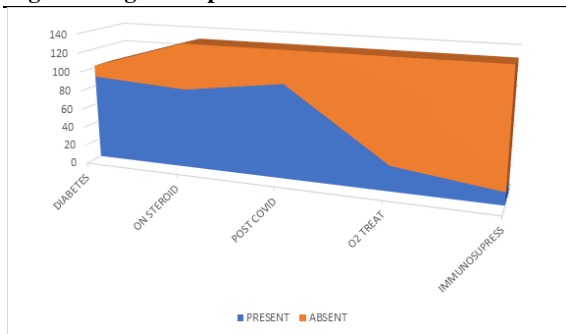
affected with Floor of Orbit (Roof of Maxillary Sinus).



**Figure 1: Sex Distribution**



**Figure 2: Age Group**



**Figure 3: Risk Factors**

**Table 1: Sex Distribution**

Male	86
Female	36

**Table 2: Age Distribution**

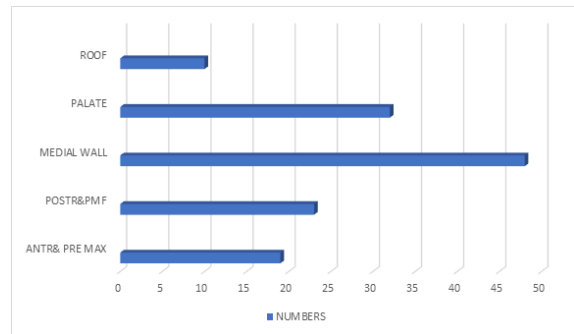
Age group	Numbers
0-20 Years	07
21-40 Years	88
41-60 Years	23
Above 60 Years	14

**Table 3: Risk Factors**

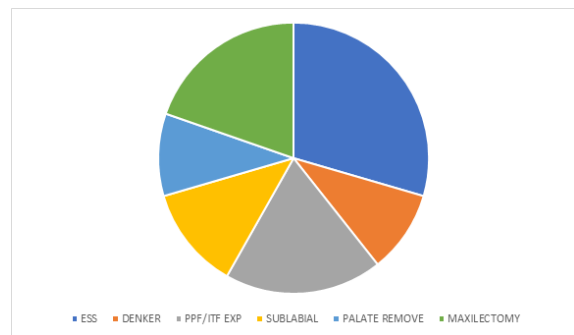
Factors	Present	Absent
Diabetes	90	42
On steroid	84	48
Post covid-19	98	34
Oxygen treatment	26	106
Immunosupresion drugs	13	119

**Table 4: Maxillary Sinus Walls Involvement.**

Maxillary Sinus Wall	Numbers
Antero Lateral & Pre-Maxilla	19
POSTR & PMF & ITF	23
Medial Wall	48
Floor (Palate)	32
Roof Of Maxillary Sinus	10



**Figure 4: Maxillary Sinus Involvement**



**Figure 5: Types of Surgery**

[Table 5 and Figure 5] shows the various types of Surgeries performed for disease clearance in our study. Endoscopic Sinus Surgery with Debridement was done for 36 cases, followed by various types of Maxillectomy in 24 cases. Endoscopic Medial Maxillectomy (Denker's Procedure) 12 cases, Exposure of Pterygo Palatine Fossae and Infra Temporal Fossae in 23 cases, Sub Labial approach for Pre-Maxillary Region in 15 cases and Palatectomy in 12 cases.

**Table 5: Types of Surgical Procedures**

Surgical procedures	Numbers
Endoscopic debridement	36
Denker procedure	12
Ppf/itf exposure	23
Sub labial approach	15
Palate removal	12
Maxillectomy	24

## DISCUSSION

The Nomenclature of fungal infection is based on Anatomic site localization rather than by Mycologic Classification. For the Head and Neck region it was classified into, Nasal, Rhino-Orbital, Rhino-Orbito-Cerebral types. Other accepted forms are Pulmonary, Cutaneous, Disseminated, Gastro Intestinal and Miscellaneous.

Rhino-Orbital-Cerebral-Mucormycosis (ROCM) occurs commonly in Post COVID\_19 and Poorly controlled Diabetes Mellitus especially with Diabetic Keto Acidosis, Iron Overload, patients on corticosteroid and Neutropenia related Haematologic malignancies.

The Fungi produces its pathologic lesions by its Angio invasion, followed by Thromboembolism and Tissue necrosis. This fungi have a Predilection for Internal Elastic Lamina of arteries. Later it will separate the Internal Elastic lamina from Media and causes Extensive Mucosal Damage resulting in Thrombus Formation followed by Ischemia of the feeding area. Infarcted tissues favors the Mucor growth by creating suitable environment. Poor Blood supply prevents the Effects of Systemic Medical Therapy to control the growth. Orbit was involved secondarily via Communicating Foramina or Venous channels from nasal cavity. Cranium is involved through the Cribriform plate, through Orbital Apex and Roof of Ethmoid (Fovea Ethmoidalis).<sup>[9]</sup>

Song G et al study reveals that 99 cases of Post Covid -19 Fungal infections, 5% cases are due to Aspergillosis and 7% of cases are due to Mucormycosis. Their study showed that Impaired T Cell immunity along with the Immunocompromised state is very important for the Pathogenesis of Mucormycosis.<sup>[10]</sup>

Waiting for Culture Report for Initiation of Treatment is not a mandatory one. Clear clinical picture of Mucor and Positive Nasal Smear report is enough to start Antifungal treatment. Diagnosis made upon by early Clinical Symptoms, Endoscopic Findings and Radiological Imaging such as CT and MRI to assess the Extent of tissue Involvement. Early Diagnosis and Proper treatment will lead to good results with reduced chances of recurrence.<sup>[11]</sup>

CT -PNS shows the Bony Landmark clearly and MRI is Inconclusive in early phase of Disease, later on it reveals the soft tissue status of involved regions by that the Surgical plan was modified. MRI shows Hypo to Iso Intense lesions on T1 images, and If the T2 image shows Hypo intense lesions it Indicates Fungal elements, which concentrate Iron and Manganese. Post Contrast Images shows Intense

Enhancement of involved sinuses. There may be Heterogeneous Opacity or Complete Hypo intense lesions due to Tissue Necrosis produced by Mucormycosis.<sup>[12]</sup>

Surgical debridement should be done in Early phase itself and it should be Aggressive manner. The Criteria to stop the procedure was If there is Fresh Bleeding from the tissues and Feeling of pain sensation in case of Local Anaesthesia. Endoscopic Sinus Surgery with Debridement of involved tissues is the mainstay of treatment. If there is difficulty to reach more Posterolateral wall of Maxillary sinus then Sub Labial Approach will be better for that situation. For Pre- Maxillary region involved cases also Sub Labial approach useful. Many cases are presented with Pre Maxillary swelling and it was drained by this approach.

In case of Pterygo Palatine Fossae (PPF) and Infra Temporal Fossae (ITF) involved cases, Endoscopic Medial Maxillectomy (Denker's Procedure) or Extended Medial Maxillectomy can be done. Naso Lacrimal System Should be dealt properly to avoid Post Operative Epiphora in this type of procedures. Mucormycosis involved in PPF and ITF will be presented as Necrosis of Fat which was the prominent content of that region and Muco purulent discharge. Most of the time the Internal Maxillary Artery found as a Cord like structure due to Thrombosis. Atmost care should be taken for Internal Maxillary Artery haemostasis, because Post Operative Bleeding from the Cut End of the vessel is a troublesome.

Ophthalmic Surgeon help is Mandatory if the disease extended Intra Ocularly. Extra Conal involved cases may be treated by Endoscopic Orbital Decompression by incising the Medial wall of the Orbit. Other Extensive involved cases need Orbital Exentration or Enucleation or Eviceration. Palatal lesions depending upon its extent treated by various procedures like Eschar removal alone, Eschar removal along with Curettage of Palate, Palatectomy and later on with Flap cover. Patients presenting with Loosening of teeth shows that Alveolar Process of Maxilla is involved. This type of cases treated by Resection of Alveolar process alone and if there is adjacent Palate also involved, treated by Sub Total Maxillectomy.

Extensive and in Recurrent Lesions Maxillectomy is the treatment of choice. Dental Surgeons help is very important for Post Operative Obturator and Further follow up of Maxillectomy cases. Specimen of operated tissues of all cases should be sent for Histo Pathological Examination, and Fungal Culture, which was very essential for both treatment part and

also for Documentary Evidence. This should be Followed by Systemic Amphotericin. Good Glycaemic Control is very important in Controlling the Disease Spread and also reducing the Recurrence Rate.

After Discharge all patients are advised for regular Weekly Follow up for Endo Cleaning and if needed Revision Debridement. All Patients are maintained with Salvage therapy with TabPosaconazole 300mg BID on first day followed by 300 OD for 4-6 weeks.

## CONCLUSION

In Our Study Males and 21-40 years of age group are commonly affected. Majority of cases are associated with Diabetes, Post Covid Status and Oxygen treatment. Medial wall of Maxillary sinus was affected more in number followed by Posterior wall and Floor. Endoscopic Sinus Surgery and Maxillectomy was done in more cases, followed by Pterygo Palatine Fossae and Infra Temporal Fossae Exposure. Maxillectomy and Palatectomy done for Extensive Palatal involved and Recurrent cases.

## REFERENCES

1. Ameen M, Arenas R, Martinez-Luna E, Reyes M, Zacarias R. The Emergence of Mucormycosis as a Opportunistic Fungal Infection. *Inter J Dermatol* 2007; 46: 380- 384.
2. Metzen D, Bohm H, Zimmermann M, Reuther T, Kubler AC, Muller Richter UD. Mucormycosis of Head and Neck, *J CraniomaxillofacSurg* 2012; 40: e321-7.
3. Jones AC, Bentsen TY, Fredman PD. Mucormycosis of Oral cavity, *Oral Surg Oral Med Oral Pathol* 1993; 75: 455-60.
4. A. Urs, H.Singh, S.Mohanty and P.Sharma. "Fungal Osteomyelitis of Maxillofacial Bones: Rare Presentation" , *Journal of Oral and Maxillo Facial Pathology*, Vol.20, no.3, p.546. 2016.
5. J.A. Kumar, P.Babu, K.Prabu, and P.Kumar, " Mucormycosis in Maxilla: Rehabilitation of Facial Defects using Interim Removable Prosthesis: a case report. *Journal of Pharmacy and Bioallied Sciences*, vol 5, no. 2, p. S163. 2013.
6. A. Chakrabarti and R.Singh , " Mucormycosis in India : unique features" *Mycoses*, vol.57, pp 85-90, 2014.
7. Tugsel Z, Sezer B, Akalin T. Facial Swelling and Palatal Ulceration in a Diabetic Patient. *Oral Surg ,Oral Med, Oral Patho,Oral Radio, Endod*, 2004; 98: 630-636.
8. Cheema SA, Amin F, Five cases of Rhino Orbito Cerebral Mucormycosis. *Br J Oral Maxillofacial Surgery* 2006; 45: 161-162.
9. Petrikos G, Skiada A, Sambatakou H et al. Mucormycosis: Ten year Experience in Tertiary care centre in Greece. *Eur J Clin Microbiol Infect Dis* 2003; 22: 753-756.
10. Song G, Liang G, Liu W. Fungal Co infections associated with global Pandemic : a clinical and diagnostic perspective from china. *Mycopathologia*, 2020; 185: 599-26.
11. P.G. Duetsch, .J. Whittaker, S. Prasad. Invasive and Non Invasive Fungal Rhino Sinusitis- a Review and Update of Evidence. *Medicina* 55 (2019) 1-14.
12. M.R. Terk, D.J. Underwood, C.S. Zee, P.M. Colletti. MR Imaging in Rhinocerebral and Intracranial Mucormycosis with CT and Pathologic Correlation. *MagnReson Imaging*, 10 (1992) : pp 81-87.